

Analysis of Ultrasonographic Misdiagnosis of Cephalothoracopagus Janiceps Conjoined Twins: A Case Report

Mehnoosh Torkzaban¹ , Nesa Rajabpoor Nikoo², Ateeh Kalateh³, Mahboobeh Shirazi^{4*} 

1. Department of Radiology, Thomas Jefferson University Hospital, Philadelphia, PA, United States
2. Shohada Hospital, Qom, Iran
3. Department of Obstetrics and Gynecology, North Khorasan University of Medical Sciences, Bojnurd, Iran
4. Maternal, Fetal and Neonatal Research Center, Tehran University of Medical Sciences, Tehran, Iran

Article Info

 [10.30699/jogcr.5.3.27](https://doi.org/10.30699/jogcr.5.3.27)

Received: 2020/05/05;
Accepted: 2020/05/27;
Published Online: 12 Aug 2020;

Use your device to scan and read the article online



ABSTRACT

Background & Objective: Conjoined twins (CTs) are rare complications of monozygotic twinning. Cephalothoracopagus is the rarest subtype of CTs and occurs once in every 58 sets of conjoined twins or once in every three million births. Here we present such a case and analyze the possible reasons for ultrasonographic misdiagnosis and recommend solutions to avoid it.

Case Report: In this article, we have reported a case of Cephalothoracopagus Janiceps twinning. The ultrasonographic diagnosis was missed at 7 and 12 weeks scans. Increased thickness of nuchal translucency and absent nasal bone was observed alongside with suspected gastroschisis. The patient was referred for further evaluation at 13-14 weeks of pregnancy. Unexpectedly, two alive fetuses were reported fused in the head, thorax, and abdomen. Because of the poor prognosis, counseling was provided for parents and elective medical pregnancy termination was carried out. We have analyzed the possible reasons for ultrasonographic misdiagnosis.

Conclusion: Without applying a standardized scanning of the entire uterus both in a longitudinal and transverse approach in early pregnancy, cephalothoracopagus twinning may be misdiagnosed with a singleton pregnancy. A high level of concerns may raise for conjoined cephalothoracopagus twinning in case of finding a single fetal pole with an irregular body outline and a disproportionately large head in the presence of two separate fetal hearts in early pregnancy. Two fused heads with two brains and two sets of lower and upper extremities do confirm the diagnosis.

Keywords: Cephalothoracopagus janiceps, Conjoined Twins, Ultrasonographic misdiagnosis

Corresponding Information:

Mahboobeh Shirazi, Maternal, Fetal and Neonatal Research Center, Tehran University of Medical Sciences, Tehran, Iran .
Email: Mahboobehshirazi4@gmail.com



Copyright © 2020. This is an original open-access article distributed under the terms of the Creative Commons Attribution-noncommercial 4.0 International License which permits copy and redistribution of the material just in noncommercial usages with proper citation.

Introduction

Conjoined twinning (CT) is a rare complication of monozygotic twinning. The frequency of CT is approximately 2:100,000 gestation, while the true incidence is around 0.5: 100,000 live births (1,2). The incidence is three times higher among female than male twines (2). In humans, monozygotic monoamniotic twins develop when an implanted blastocyst splits at about 9–13 days after fertilization. Failure to undergo a complete spillage of the embryonic disc at or later than 14 days results in conjoined twin development (fissure theory) (2,3,4). The etiology of CT is obscure and none of race, consanguinity, hereditary, birth order, maternal age, acute and chronic diseases during pregnancy, or maternal exposure has revealed any association with CT (3,5). Conjoined twinning has been reported in twine and triplet pregnancies following assisted reproductive techniques such as in-

vitro fertilization and intracytoplasmic sperm injection (6,7). Conjoined twins are classified according to the most prominent site of attachment, plus “pagus”, a term that means “fixed” in Greek (2). Cephalothoracopagus is the rarest subtype of CTs and occurs once in every 58 sets of conjoined twins or once in every three million births (8,9); it refers to twins with fused head and thorax but separate pelvis and limbs. If the single fused head has two faces each looking in opposite directions, the twins are referred to as Cephalothoracopagus janiceps twins (8,10). The term janiceps has its origin in Janus, the two-faced Roman god. When the two faces are asymmetrical and only one normal face can be seen alongside with a second incomplete face (single naris, cyclopic eyes, synotic ears, a proboscis, or two small eyes in a single palpebral fissure), it is called cephalothoracopagus

janiceps monosymmetros (10). Here we present such a case.

Case Report

A 33-year-old G2P1 pregnant woman, who had conceived spontaneously and had an unremarkable medical history with no history of drug, alcohol or cigarette smoking, underwent her early pregnancy ultrasound. The scan revealed one fetal pole, one yolk sac, and a normal fetal heart rate (FHR). The crown-rump length (CRL) was 12 mm equal to 7weeks 3 days of pregnancy. She was scanned next time for aneuploidy screening ultrasound at 11 weeks, 4 days of the last menstrual period (LMP). The gestational age (GA) based on the CRL was equal to 12 weeks, 1 day of pregnancy. The thickness of the nuchal translucency (NT) was reported as 4 mm. The radiologist had reported possible technical errors in NT measurement and inability in nasal bone (NB) visualizing due to unfavorable fetal position. A hyperechoic herniated mass was also visualized at the level of the anterior abdominal wall and Gastroschisis was suspected. The

patient was referred to a tertiary health center, (Yas Hospital, Tehran, Iran), for further evaluation. The next ultrasound exam was performed at 13-14 weeks of pregnancy. Unexpectedly, two alive fetuses were reported fused in head, thorax, and abdomen. The ultrasound diagnosis of cephalothoracopagus CTs was made. Because of the poor prognosis, counseling was provided for parents and elective medical pregnancy termination by misoprostol was carried out. The expelled twins were fused at the cranium, thorax, and abdomen to the umbilicus. Twines had a shared placenta and umbilical cord. The faces were dissimilar and on opposite sides of the head, 90 degrees to the separate spines. There was one normal face with two eyes, one complete nose, and one mouth, and one set of low-set ears (Figure 1A), and the opposing face had incomplete facial features as one cyclopic eye and irregular fused nares and mouth orifices (Figure 1B). The arms and legs of each of the twins were of similar length and development and followed the orientation of the spine (Figure 1C). The twines' sex was not obvious but more likely were females.

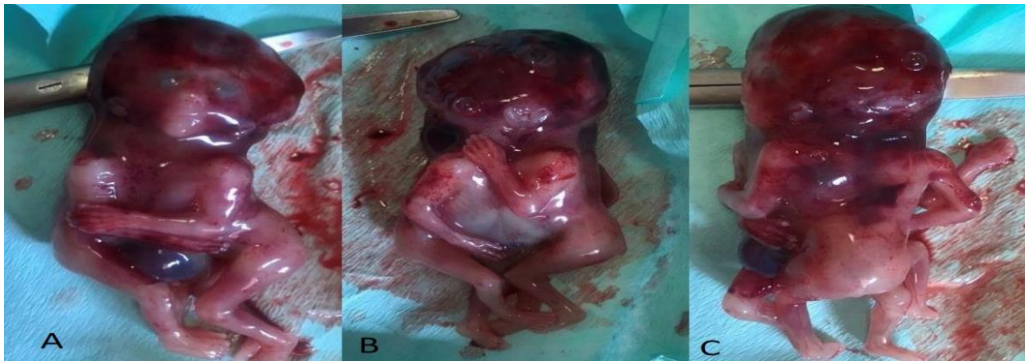

Figure 1. A. Normal face with two eyes, one complete nose and one mouth, and one set of low set ears; B. Incomplete facial features as one cyclopic eye and irregular fused nares and mouth orifice; C. The arms and legs of each of the twins were of similar length and development and followed the orientation of the spine

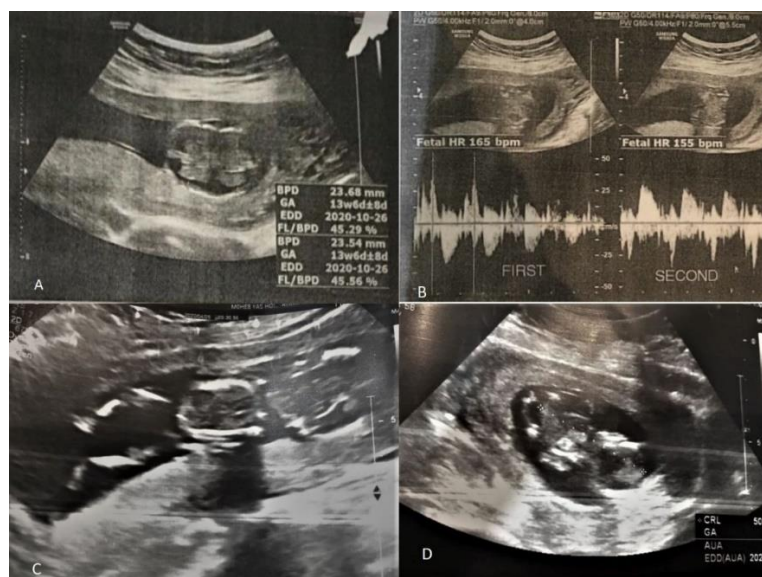


Figure 2. A. Longitudinal section of twins, mimicking singleton pregnancy at 11 weeks 6 days of pregnancy; B. Fused brains at 13-14 weeks of pregnancy; C. Two separate beating heart at 13-14 weeks of pregnancy; D. Longitudinal section of twins at 13-14 weeks of pregnancy.

Discussion

The worldwide use of the ultrasound in prenatal screening for Down syndrome provides the diagnosis of conjoined twinning in early pregnancy. Since all CTs are monochorionic monoamniotic, when only one yolk sac is seen alongside two embryos in very early pregnancy, the index of suspicion should be raised. Two of first-trimester sonographic indications for possible conjoined twinning are: 1-bifid appearance of a sole fetal pole in the first trimester seen before 10 weeks of gestation, and 2- visualization of two hearts or two stomachs (3). From 8 weeks of gestation, fetal activity increases progressively, which facilitates the differential diagnosis between conjoined and non-conjoined monoamniotic twins (1). The first trimester (11-13w+6days) ultrasound is the best method for early diagnosis of CTs (3).

The earliest prenatal diagnosis of cephalothoracopagus twins was reported by Lam *et al.* 1998 (11). The diagnosis was made by vaginal ultrasound examination at 8 weeks' gestation from the findings of a single fetal pole with an irregular body outline, a disproportionally large head, and two separate cardiac pulsations and was confirmed after rescanning at 11 weeks (11). While early diagnosis of conjoined twins is feasible, it is not always easy in cephalothoracopagus twinning due to extensive conjoining; a single fused head and thorax, and limited fetal movement as was seen in our case.

Due to the monoamniocity of the conjoined twins, a single yolk sac alongside a single CRL and normal fetal heart were observed at 7-8 weeks of gestation in our case; mimicking a singleton pregnancy and substantial missing of the second fetal heart (Figure 2A). When the second ultrasound scan was performed at 11 weeks 4 days of LMP in our case for NT measurement, the operator reported a fetus with normal fetal heart, increased NT, non-visualized NB, and herniated mass at the ventral abdominal wall, but yet to notice the second fetal heart and fused brains. Following the detection of the aforementioned anomalies, a thorough evaluation of the fetal thorax and cranium via scanning the entire uterus both in a longitudinal and transverse approach could be helpful in revealing two separate hearts, fused brains, and duplicated extremities, leading to the accurate diagnosis of CTs. Increased NT, cystic hygroma, and abdominal wall defects are the most common findings in conjoined twins (12). Currently, certain congenital fetal anomalies are diagnosed even before the twentieth week of gestation with the use of high-resolution ultrasound equipment, but without following a standardized approach to fetal ultrasound and in case of lack of suspicion to any abnormal condition, misdiagnosis may happen (13,14).

The final ultrasound scan was performed at 13-14 weeks of GA in our reported case. The diagnosis of cephalothoracopagus CTs was made by finding one shared placenta and umbilical cord, two fused brains without separating bony skull, two deformed spinal columns, one common thoracic cage with two separate

beating hearts and one stomach, two separate sets of lower and upper extremities, and two separate pelvises. One of the twins had cystic hygroma in the posterior neck. The estimated GA based on both twines' approximate CRL was 13 weeks 6 days (Figures 2B, 2C and 2D).

The next step after diagnosis of conjoined twinning is a prognostic assessment to propose timely medical termination of pregnancy in case of non-viability and prevent complicated surgical delivery. In cephalothoracopagus CTs, due to the fusion of the heads and abnormal arrangement of the superior central nervous system, no attempt at surgical separation should be considered and the prognosis is very poor (15). We arranged a medical pregnancy termination accordingly. The recurrence risk for conjoined twins appears to be negligible (5).

Conclusion

In Cephalothoracopagus twinning a single yolk sac alongside a single CRL and normal fetal heart at 7-10 weeks of gestation may mimic a singleton pregnancy and lead to missing the second fetal heart and fused brains without applying a standardized scanning of the entire uterus both in a longitudinal and transverse approach. A high level of concerns may raise for conjoined cephalothoracopagus twinning in case of finding a single fetal pole with an irregular body outline and a disproportionally large head in the presence of two separate fetal hearts in early pregnancy. Two fused heads with two brains and two sets of lower and upper extremities do confirm the diagnosis.

Acknowledgments

The authors would like to thank all those who helped them writing this paper.

Conflict of Interest

Authors declared no conflict of interests.

References

1. Pajkrt E, Jauniaux E. First-trimester diagnosis of conjoined twins. *Prenatal Diagnosis: Published in Affiliation With the International Society for Prenatal Diagnosis.* 2005 Sep;25(9):820-6. [DOI:10.1002/pd.1267] [PMID]
2. Spitz L. Conjoined twins. *Prenatal Diagnosis: Published in Affiliation With the International Society for Prenatal Diagnosis.* 2005 Sep;25(9):814-9.3- [DOI:10.1002/pd.1268] [PMID]
3. Cuillier F, Dillon KC, Grochal F, Scemama JM, Gervais T, Cerekja A, Piazze J. Conjoined twins: what ultrasound may add to management. *J Prenat Med.* 2012 Jan;6(1):4.
4. Kaufman MH. The embryology of conjoined twins. *Child's Nerv Sys.* 2004 Aug 1;20(8-9):508-25. [DOI:10.1007/s00381-004-0985-4] [PMID]
5. Mutchinick OM, Luna-Muñoz L, Amar E, Bakker MK, Clementi M, Cocchi G, da Graça Dutra M,

- Feldkamp ML, Landau D, Leoncini E, Li Z. Conjoined twins: a worldwide collaborative epidemiological study of the International Clearinghouse for Birth Defects Surveillance and Research. In *American Journal of Medical Genetics Part C: Seminars in Medical Genetics* 2011 Nov 15 (Vol. 157, No. 4, pp. 274-287). Hoboken: Wiley Subscription Services, Inc., A Wiley Company. [DOI:10.1002/ajmg.c.30321] [PMID] [PMCID]
6. Mendilcioglu I, Simsek M. Conjoined twins in a trichorionic quadruplet pregnancy after ovulation induction with clomiphene citrate. *Fetal Diagn Therap.* 2008;24(1):51-4. [DOI:10.1159/000132407] [PMID]
 7. Talebian M, Rahimi-Sharbat F, Shirazi M, Teimoori B, Izadi-mood N, Sarmadi S. Conjoined twins in a monochorionic triplet pregnancy after in vitro fertilization: a case report. *Iran J Reproduct Med.* 2015 Nov;13(11):729.
 8. Chen CP, Shih JC, Shih SL, Huang JK, Huang JP, Lin YH, Wang W. Prenatal diagnosis of cephalothoracopagus janiceps disymmetros using three-dimensional power Doppler ultrasound and magnetic resonance imaging. *Ultrasound Obstet Gynecol.* 2003 Sep;22(3):299-304. [DOI:10.1002/uog.226] [PMID]
 9. Yılmaz-Semerci S, Güzelbey T, Kurnaz D, Kalkan Ş, Çetinkaya M. A rare case of cephalothoracopagus janiceps conjoined twins. *Turk J Pediat.* 2018 Nov 1;60(6):751-4. [DOI:10.24953/turkjped.2018.06.020] [PMID]
 10. Slager UT, Anderson VM, Handmaker SD. Cephalothoracopagus janiceps malformation: a contribution to the pathogenesis of cerebral malformation. *Archives of neurology.* 1981 Feb 1;38(2):103-8. [DOI:10.1001/archneur.1981.00510020061009] [PMID]
 11. Lam YH, Sin SY, Lam C, Lee CP, Tang MH, Tse HY. Prenatal sonographic diagnosis of conjoined twins in the first trimester: two case reports. *Ultrasound in Obstetrics and Gynecology: The Official Journal of the International Society of Ultrasound in Obstetrics and Gynecology.* 1998 Apr;11(4):289-91. [DOI:10.1046/j.1469-0705.1998.11040289.x] [PMID]
 12. Melo Â, Dinis R, Portugal A, Sousa AI, Cerveira I. Early prenatal diagnosis of parapagus conjoined twins. *Clinics and practice.* 2018 Mar 28;8(2). [DOI:10.4081/cp.2018.1039] [PMID] [PMCID]
 13. Shirazi M, Abbariki E, Pirjani R, Akhavan S, Dastgerdy E. Congenital microtia in a neonate due to maternal isotretinoin exposure 1 month before pregnancy: Case Report. *J Obstet Gynaecol Res.* 2015 Jun;41(6):975-8. [DOI:10.1111/jog.12644] [PMID]
 14. Shirazi M, Moosavi SA. Response to "Letter to Congenital microtia in a neonate suspected of isotretinoin exposure one month before pregnancy: A case report". *J Obstet Gynaecol Res.* 2015 Dec;41(12):2010. [DOI:10.1111/jog.12823] [PMID]
 15. Cîrstoiu MM, Filipoiu FM, Brătilă EL, Berceanu C, Cîrstoiu FC, Budu VA, Bulescu IA, Munteanu O. Morphological study of cephalothoracopagus deradelphus type conjoined twins. A case report. *Rom J Morphol Embryol.* 2016 Jan 1;57(1):249-52.

How to Cite This Article:

Torkzaban M, Kalateh A, Rajabpoor Nikoo N, Shirazi M. Analysis of Ultrasonographic Misdiagnosis of Cephalothoracopagus Janiceps Conjoined Twins: A Case Report. *J Obstet Gynecol Cancer Res.* 2020; 5 (1) :27-30

Download citation:

[BibTeX](#) | [RIS](#) | [EndNote](#) | [Medlars](#) | [ProCite](#) | [Reference Manager](#) | [RefWorks](#)