

## Perineal Leiomyoma: A Case Report

Sarmad Nourooz Zadeh<sup>1</sup> , Sedigheh Ghasemian Dizajmehr<sup>\*2</sup> ,  
Farzaneh Rashidi Fakari<sup>3</sup> , Hania Fattahi<sup>4</sup> , Mohsen Ghasemian<sup>5</sup>

1. Medical Doctor, School of Medicine, Urmia University of Medical Sciences, Urmia, Iran
2. Department of Obstetrics and Gynecology, School of Medicine, Urmia University of Medical Sciences, Urmia, Iran
3. PhD, Assistant Professor, Department of Midwifery, School of Medicine, North Khorasan University of Medical Sciences, Bojnurd, Iran
4. Resident of Pathology, School of Medicine, Urmia University of Medical Sciences, Urmia, Iran
5. Medical Doctor, School of Medicine, Ardabil University of Medical Sciences, Ardabil, Iran

### Article Info

 [10.30699/jogcr.5.2.54](https://doi.org/10.30699/jogcr.5.2.54)

**Received:** 2020/08/31;

**Accepted:** 2020/09/13;

**Published Online:** 30 Oct 2020;

Use your device to scan and read the article online



### ABSTRACT

**Background & Objective:** Leiomyomas are tumors of the soft tissues. The incidence of myomas within the perineum is absolutely rare and only a few reports have been made on the matter. We herein report a case of perineal myoma in a virgin woman, which was successfully excised.

**Case Report:** We present a 35-year-old virgin woman, with complaint referred to a mass in her perineum which had first exhibited signs 5 years prior to the time she referred to us and had increased in size in a steady manner ever since. The mass had caused no gynaecologic, rectal or urinary symptoms. Clinical examination revealed a painless, mobile mass (6cm\*6cm) with [unknown consistency] in the right perineum with extension to the distal of the labium majus of the same side.

**Conclusion:** Treatment of symptomatic leiomyomas relies on surgical excision of the mass. However, the surgical method of choice is a matter of debate in previous studies.

**Keywords:** Leiomyoma, Perineum, Tissue

### Corresponding Information:

Sedigheh Ghasemian Dizajmehr, Department of Obstetrics and Gynecology, School of Medicine, Urmia University of Medical Sciences, Urmia, Iran, Email: dr.ghassemian@yahoo.com Tel: +98 9144712901



Copyright © 2020, This is an original open-access article distributed under the terms of the Creative Commons Attribution-noncommercial 4.0 International License which permits copy and redistribution of the material just in noncommercial usages with proper citation.

## Introduction

Leiomyomas are tumors of the soft tissues. As the most commonly occurring benign neoplasm of the reproductive system in women of childbearing age, these tumours usually develop within the uterus (1). The incidence of myomas within the perineum is absolutely rare and only a few reports have been made on the matter. Although the etiology of these tumors is not completely understood, it is known that myomas are especially dependent on reproductive hormones and occur only, but for a sole exception, in the reproductive age (2). A host of other risk factors have also been suggested to affect the development of myomas, the degree of their influence is yet to be determined.

We herein report a case of perineal myoma in a virgin woman, which was successfully excised and further evaluated.

## Case Report

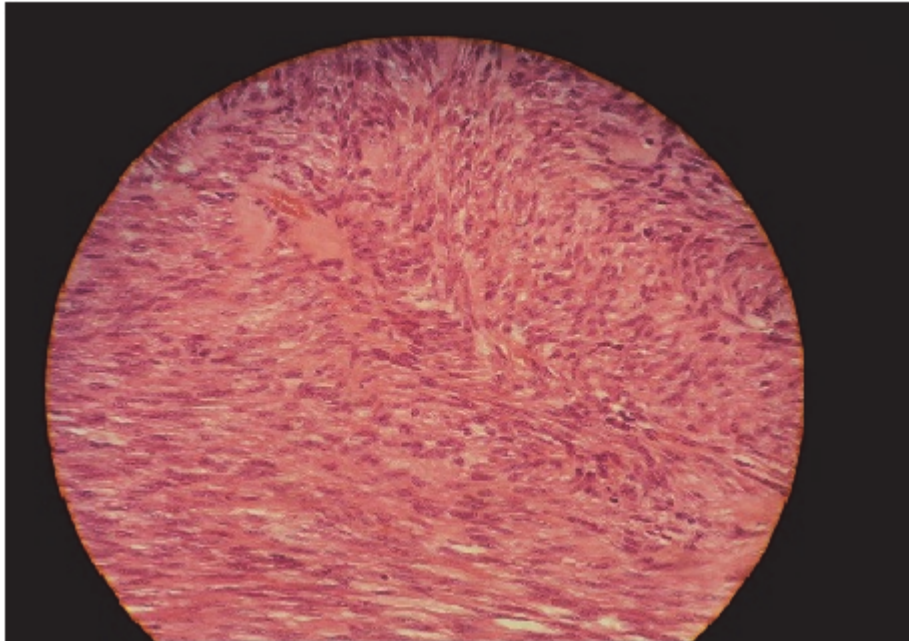
A 35 year old virgin woman was admitted to the gynaecology department of Shahid Motaharri hospital

(Urmia, Iran) in 3 years ago. Her complaint referred to a mass in her perineum which had first exhibited signs of presence 5 years prior to her referral and had increased in size in a steady manner ever since. The mass had caused no gynaecologic, rectal or urinary symptoms. Clinical examination revealed a painless, mobile mass (6cm\*6cm) with [unknown consistency] in the right perineum with extension to the distal of the labium majus of the same side. Due to cultural considerations, the virginity of the patient prevented us from exploring her genitalia further. Examination of the rectum revealed no abnormalities. Colour Doppler ultrasound was performed to determine vascularity and precise dimensions: a heterogeneous mass (5 cm\*5 cm\*4 cm) was observed in the distal section of the right labium majus with extension to the perineum of the same side. A high vascular flow and decreased resistance (RI: 0.42) was present throughout the mass. The mass exhibited rich vascularization.

Excision of the mass was performed under spinal anaesthesia. A 4 cm elliptical incision was made lateral to the Hymen, approximately 2 cm to the right of the

perineum at the site of maximal bulging caused by the mass. The mass exhibited no signs of loco-regional invasion. The mass (6 cm\*6 cm) was excised without the incidence of haemorrhagic difficulties. The site of surgery was repaired with maintaining proper

haemostasis (Figure 1). Following the surgery, the patient retained normal urinary and anorectal sphincter function. Written informed consent was obtained from the patient



**Figure 1.** Elongated spindle cells with Fibrillary acidophilic cytoplasm arranged in intersecting fascicles.

## Discussion

Leiomyomas arise from mesenchymal origins and commonly exhibit benign and non-invasive behavior (3). A 7 year study revealed that about 3.8% of all benign tumors are leiomyomas and the areas most affected are the skin and smooth muscles throughout the body (4). These masses constitute the most commonly occurring pelvic tumor in the female population, almost always developing in those of childbearing age. Studies such as the Nurses' Health Study II and that performed by Braid *et al.* in the United States, cover only a section of this age spectrum. Other studies, such as that carried out by Downes *et al.* in Europe, were only performed on patients whose masses had exhibited symptoms, thus excluding the population with asymptomatic leiomyomas from the prevalence estimation. It is speculated that the expression of oestrogen and progesterone receptors plays a key role in the development of leiomyomas (5). Other factors such as trauma, inflammation and dietary habits may also influence the development of leiomyomas. Perineal leiomyomas are extremely rare and few case reports have been made regarding their existence. Therefore, when encountering such masses in the perineum it is important to take more malignant and invasive diagnoses, such as leiomyosarcomas and invasive angiosarcomas, into consideration. As von Waagner *et al.* considered the possibility of a low grade sarcoma

(6). Therefore, imaging modalities such as Magnetic Resonance Imaging and colour Doppler ultrasound may be used to assess attributes of masses, such as size, consistency, vascularity and invasion, aiding the physician in their diagnosis. However, definite diagnosis is achievable solely through histologic assessment of the presenting mass. Treatment of symptomatic leiomyomas relies on surgical excision of the mass. Although the surgical method of choice is a matter of debate in previous studies. Ben Haj Hassine *et al.* suggested laparoscopic interventions prior to performing perineal incisions (7). Other studies, such as those performed by von Waagner *et al.*, Shuch *et al.*, Brito *et al.* and Sui *et al.* suggest a more direct approach by perineal incision (2, 6, 8).

## Conclusion

Treatment of symptomatic leiomyomas relies on surgical excision of the mass. However, the surgical method of choice is a matter of debate in previous studies.

## Acknowledgments

The authors thank all the staff member of obstetrics and gynecology department of Motahhari Hospital, Urmia for their help and suggestions.

## Conflict of Interest

Authors declared no conflict of interests.

## References

1. Shuch B, Triaca V, Raz S. Leiomyoma of the Perineum. *Female Pelvic Med Reconstr Surg.* 2007;13(3):145-7. [DOI:10.1097/SPV.0b013e3180622285]
2. Sui YX, Sun C, Lv SL, Batchu N, Zou JK, Du J, et al. Perineal leiomyoma in a postmenopausal woman: A case report. *Oncol Lett.* 2016;12(3):2045-7. [DOI:10.3892/ol.2016.4830] [PMID] [PMCID]
3. Weiss SW. Smooth muscle tumors of soft tissue. *Adv Anat Pathol.* 2002;9(6):351-9. [DOI:10.1097/00125480-200211000-00004] [PMID]
4. Myhre-Jensen O. A consecutive 7-year series of 1331 benign soft tissue tumours. Clinicopathologic data. Comparison with sarcomas. *Acta Orthop Scand.* 1981;52(3):287-93. [DOI:10.3109/17453678109050105] [PMID]
5. . !!! INVALID CITATION !!! (5).
6. von-Waagner W, Liu H, Picon AI. Giant Perineal Leiomyoma: A Case Report and Review of the Literature. *Case Reports in Surgery.* 2014;2014. [DOI:10.1155/2014/629672] [PMID] [PMCID]
7. Ben Haj Hassine MA, Arfaoui R, Siala H, Trabelsi H, Rachdi R. Soft-tissue tumor of the perineum: an exceptional case of bilateral perineal myoma. *Clin Case Rep.* 2015;3(2):99-101. [DOI:10.1002/ccr3.164] [PMID] [PMCID]
8. Oliveira Brito LG, Falcao Motoki L, Magnani PS, Sabino-de-Freitas MM, Magnani Landell GA, Quintana SM. Giant perineal leiomyoma incidentally manifested at a recent episiotomy site: case report. *J Minim Invasive Gynecol.* 2011;18(2):267-9. [DOI:10.1016/j.jmig.2010.12.010] [PMID]

### How to Cite This Article:

Nourooz Zadeh S, Ghasemian S, Rashidi fakari F, Fattahi H, Ghasemian M. Perineal Leiomyoma: A Case Report. *J Obstet Gynecol Cancer Res.* 2020; 5 (2) :54-56

### Download citation:

[BibTeX](#) | [RIS](#) | [EndNote](#) | [Medlars](#) | [ProCite](#) | [Reference Manager](#) | [RefWorks](#)