

Normal Assessment of Three Routine Axial Planes in Basic Fetal Neurosonogram Cannot Exclude Encephalocele: Introducing Two Cases

Fatemeh Golshahi¹, Mahboobeh Shirazi¹, Shirin Torabi², Fatemeh Rahimi Sharbaf¹, Farzaneh Nazari^{3*}

1. Department of Maternal and Fetal Medicine, Yas Hospital, Tehran University of Medical Sciences, Tehran, Iran
2. Department of Maternal and Fetal Medicine, Tehran University of Medical Sciences, Tehran, Iran
3. Department of Obstetrics and Gynecology, School of Medicine, Bushehr University of Medical Sciences, Bushehr, Iran



Article Info

[10.30699/jogcr.6.3.147](https://doi.org/10.30699/jogcr.6.3.147)

Received: 2020/12/11;

Accepted: 2020/02/17;

Published Online: 18 Jun. 2021;

Use your device to scan and read the article online



Corresponding Information:

Farzaneh Nazari,

Department of Obstetrics and Gynecology,
School of Medicine, Bushehr University of
Medical Sciences, Bushehr, Iran

Email: Nazarif78@yahoo.com

ABSTRACT

Currently, ultrasound is a well-known clinical modality for pregnancy management and has a prominent role in clinical decision-making. Accordingly, developing guidelines to outline the minimum performance standards of using ultrasound is necessary for different areas of obstetric ultrasound. The fetal brain is one of the most important assessments in anomaly scan. For a basic brain assessment, 3 axial planes are routinely defined. According to most guidelines, the fetal skull's integrity, shape, and bone density should be assessed while measuring the head size. In this paper, we present 2 cases of skull bony defect with normal routine 3 axial planes. For better detection of CNS anomalies, it is necessary to add other views such as sagittal view to three routine planes. It leads to early detection of anomalies especially in first and early second trimester. Consequently, it helps in deciding for termination, planning interventions and further management.

Keywords: Axial planes, Encephalocele, Fetus, Skull integrity, Ultrasound



Copyright © 2021, This is an original open-access article distributed under the terms of the Creative Commons Attribution-noncommercial 4.0 International License which permits copy and redistribution of the material just in noncommercial usages with proper citation.

Introduction

Central nervous system (CNS) malformations occur in 1% of all births. Accordingly, the detection of such anomalies prenatally is important. Ultrasound modality is an effective method for anomaly screening, including CNS anomalies. Especially in the antenatal period, ultrasound presents the developing fetus's anatomical record. In fetal anomaly surveys, fetal brain evaluation is an optimized approach, known as a basic examination. CNS basic examination includes 3 axial planes, allowing biometry besides cerebral structure visualization to investigate the brain's anatomical integrity. Conventionally, these planes are known as transventricular, transcerebellar, and transthalamic planes (1, 2).

Encephalocele is an anomaly of embryological and mesodermal development, leading to the genesis of a calvarial and dura defect; it may be associated with herniation of meninges, cerebrospinal fluid (CSF), and neural tissue (3). The cranium's posterior part is often involved in cephaloceles, though other parts of the

calvarium may be involved as well. Usually, it is diagnosed early in pregnancy by sonographic findings.

To diagnose encephalocele, one must demonstrate a cranial vault defect and a continuity between the intracranial structures and encephalocele contents. Identification of a skull defect is perhaps the most reliable aid in making the diagnosis of an encephalocele. Normal intracranial anatomy and cranium intactness strongly suggest the absence of calvarial pathologies.

We report the detection of 2 encephalocele cases, which could be missed by 3 routine basic fetal brain sonographic planes.

Cases Presentation

Case 1

A 25-year-old woman (gravida 1) with non-consanguineous marriage in 18 weeks of gestational

age with no personal or familial medical history was referred to our clinic for an anomaly scan. The combined screening in the first trimester (including NT, PAPP-A, Free B-hCG) was normal in her obstetric history. Two-dimensional sonography was performed using a Philips Affiniti 50 Ultrasound Machine (PHILIPS Company, Andover, USA) with a 4.5-MHz convex probe. In our assessment, at 17 weeks of gestational age, we noticed bilateral symmetric cystic masses measuring 6×7 mm, possibly originating from the occipital region of the fetus skull (upper part).

[Figure 1a](#) shows the transthalamic plane, which is the fetal head's transverse plane for measuring the head circumference and biparietal diameter. The skull's shape, integrity, size, and bone density may be assessed when the head's size is measured. As [Figure 1a](#) highlights, there is no skull defect in the parietal or frontal region, showing a completely normal transthalamic view of the fetus.

[Figure 1b](#) illustrates the transcerebellar plane, assessing posterior fossa (cerebellum, cisterna magna, cavum septum pellucidum, and falx). In this plane, also, there is no evidence of skull defect. [Figure 1c](#) highlights the transventricular plane, which is used for measuring the size of the lateral ventricle.

We did not see any evidence of bony skull defect or any protruding lesion in the 3 basic planes, but we incidentally noticed a bony defect in the parasagittal

and transorbital view, after which we performed a transvaginal scan to have a better view of the fetus. We noticed the defect in the fetal head's parieto-occipital region, which could easily be missed in a basic sonographic examination ([Figure 2](#)).

Case 2

A 34-year-old woman (gravida 2, abortion 1) was admitted to our clinic for a prenatal visit and performing a detailed anomaly scan at 22 weeks from her last menstrual period. She did not report any history of a genetic condition or congenital anomaly. Two-dimensional sonography using Mindray DC80 (Mindray, Shenzhen, China) with a 3.5-MHz convex probe revealed a single live fetus; placenta and amniotic fluid volume were normal. On ultrasonographic examination, 2 symmetric cystic structures were measured approximately 8×6.5 mm; they were protruded through the posterior and upper part of the skull. In the standard axial fetal brain planes, we did not see any defect or pathologic finding ([Figure 3](#)); however, there was a small bony defect in the parasagittal view on transvaginal sonography ([Figure 4](#)). Posterior fossa and lateral ventricles were within normal limits, and there was no sign of neural tube defect. Overall, no other anomaly was found in the detailed anomaly scan.

Also, we did not see any pathologic finding in these standard axial fetal brain planes for the second patient.

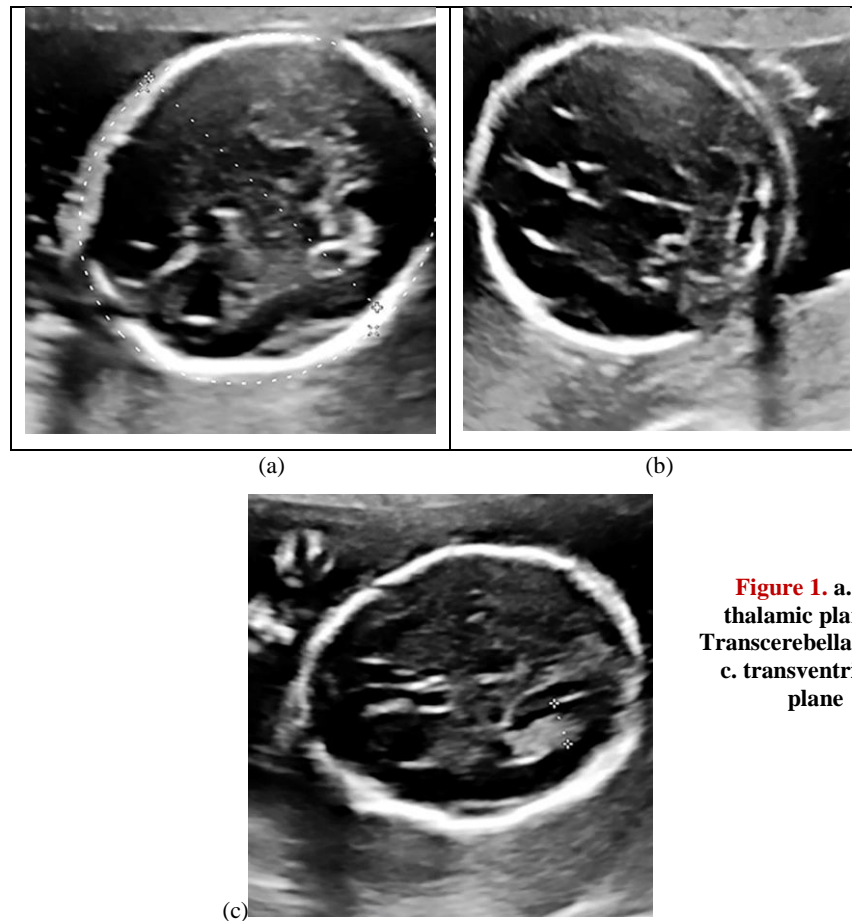


Figure 1. a. transthalamic plane; b. Transcerebellar plane; c. transventricular plane

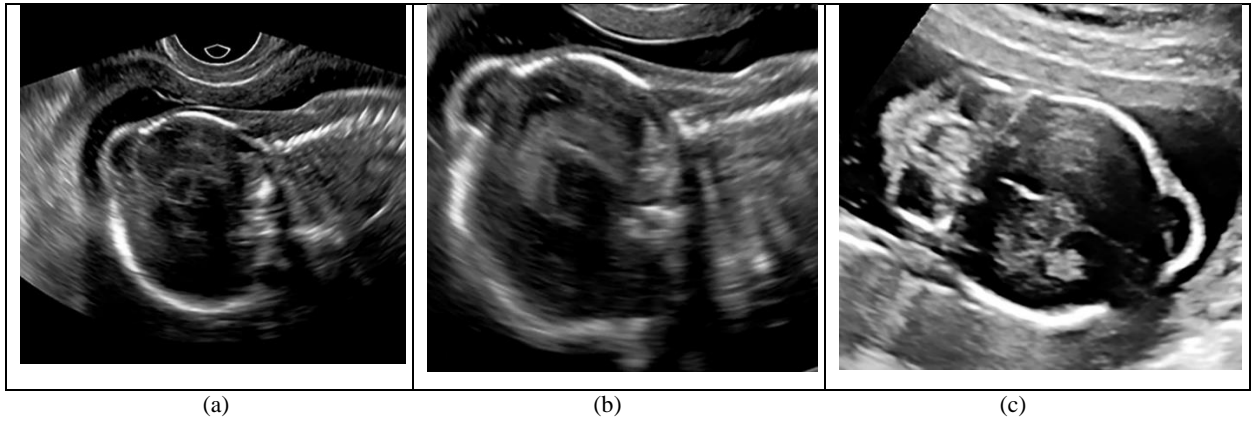


Figure 2. a. External parasagittal or Oblique plane of the brain; b. The parasagittal or Oblique plane of the brain showing lateral ventricle with the choroid plexus inside; c. Coronal view of the fetal head in the transfrontal plane, showing the interhemispheric fissure, and the ocular orbits (trans orbital)

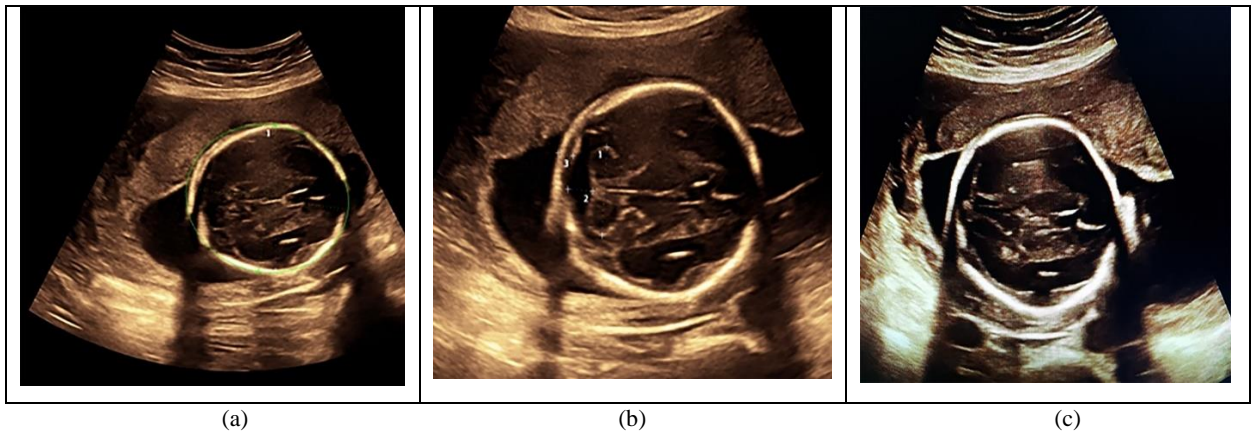


Figure 3. a. Trans-thalamic plane; b. Transcerebellar plane; c. transventricular plane

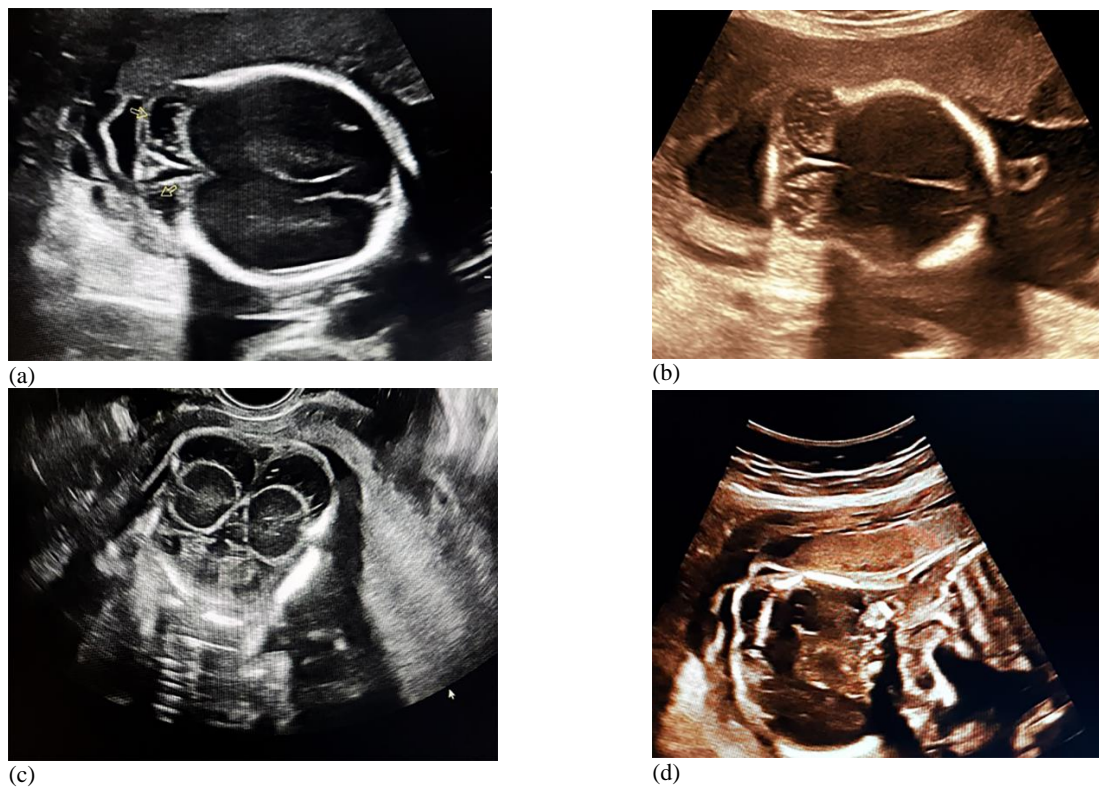


Figure 4. a, b. Transverse view of upper part of skull; c. Coronal view of the fetal head on transvaginal USG; d. The parasagittal or Oblique plane of the head

Discussion

CNS anomalies are known as one of the most prevalent malformations detected by antenatal sonography. Nowadays, prenatal detection of anencephaly using ultrasound is possible in almost 100% of cases. The diagnosis of encephalocele is usually made during the second trimester of pregnancy, around the 20th week (4). However, in some cases, the findings may be subtle, whereas, in others, the anomaly may be progressive and manifest only in late gestation or after birth.

Further, ultrasound frequently demonstrates normal anatomic variations difficult to differentiate from true malformations. Fetal cephalocele is suspected when a paracranial mass is seen on sonography (Figure 4). The diagnosis of encephalocele is typically straightforward, as the presence of brain tissue inside the sac is striking on ultrasound images. Anatomical location is used for defining cephaloceles (e.g., parietal, frontal, frontoethmoidal, occipital, etc.). Occipital cephalocele is more common in the United States and Europe, while frontal cephalocele is more common in Asia (5).

Due to the outstanding role of ultrasound in clinical decision-making and its operator-dependent nature, it is vital to develop guidelines to define minimum performance standards for this modality in different obstetric ultrasound areas. The brain anomaly scan is among the most important assessments in anomaly scan. Three axial planes are included in the CNS malformations' standard screening protocol (transthalamic, transcerebellar, and transventricular). International guidelines have defined the anatomical landmarks and methodology of these planes (5-7). The skull's shape, integrity, size, and bone density may be assessed when the head's size is measured.

In this study, 3 basic axial views of the fetal head were completely normal with no calvarial bony defect in both cases. Because we doubted the defect in other planes, we performed transvaginal sonography. In transvaginal sonography, we noticed 2 symmetric cystic masses from the occiput, which could easily be missed in axial planes. Therefore, normal assessment of 3 routine axial planes cannot exclude some major, lethal, or morbid fetal neurological problems as encephalocele.

According to the latest guidelines, scanning the 3 axial planes is not sufficient for fetal brain morphology's basic ultrasonographic evaluation. Currently, the

neurosonographic examination (8-10), i.e., evaluating the axial, coronal, and sagittal planes of the brain, is performed only for high-risk patients or for those who have brain anomaly in anomaly scan.

However, it is necessary to add other planes such as sagittal and coronal planes to 3 routine planes for better detection of CNS anomalies. It results in early anomaly detection, particularly in the first trimester and early second trimester. Consequently, it is helpful to decide on termination, plan interventions, and manage pregnancy.

Some CNS anomalies may be associated with more morbidity. Early detection would help parents make the right decision. If the parents decide to terminate the pregnancy, they have enough time for a legal abortion. This is for the reason that legal abortion in Iran is permitted under 19 weeks; one of our patients who was diagnosed at 22 weeks got an illegal abortion.

The limitation of this study is that our patients had outpatient abortions, and missed fetuses were not examined. Postmortem examination and simple radiographic studies are important to evaluate associated malformations and confirm the prenatal findings (6). These are straightforward, inexpensive, and effective methods.

Conclusion

For better detection of CNS anomalies, it is necessary to add other views such as sagittal view to three routine planes. It leads to early detection of anomalies especially in first and early second trimester. Consequently, it helps in deciding for termination, planning interventions and further management.

Acknowledgments

The authors have no acknowledgement.

Conflict of Interest

The authors have no conflicts of interest.

References

1. International Society of Ultrasound in Obstetrics & Gynecology Education Committee. Sonographic examination of the fetal central nervous system: guidelines for performing the 'basic examination' and the 'fetal neurosonogram'. *Ultrasound in obstetrics & gynecology: Official J Int Soc Ultrasound Obstet Gynecol.* 2007; 29(1):109-16. [[DOI:10.1002/uog.3909](https://doi.org/10.1002/uog.3909)] [[PMID](#)]
2. Salomon LJ, Alfirevic Z, Berghella V, Bilardo C, Hernandez-Andrade E, Johnsen SL, et al.

- Practice guidelines for performance of the routine mid-trimester fetal ultrasound scan. *Ultrasound Obstet Gynecol.* 2011; 37(1):116-26. [[DOI:10.1002/uog.8831](https://doi.org/10.1002/uog.8831)] [[PMID](#)]
3. Milani HJ, de Sá Barreto EQ, Júnior EA, Peixoto AB, Nardoza LM, Moron AF. Ultrasonographic evaluation of the fetal central nervous system: review of guidelines. *Radiol Bras.* 2019; 52(3): 176-81. [[DOI:10.1590/0100-3984.2018.0056](https://doi.org/10.1590/0100-3984.2018.0056)] [[PMID](#)] [[PMCID](#)]
 4. Ong AGJ, Rolnik DL, Menezes M, Meagher S. Early Diagnosis and Differences in Progression of Fetal Encephalocele. *J Ultrasound Med.* 2020; 39(7):1435-40. [[DOI:10.1002/jum.15217](https://doi.org/10.1002/jum.15217)] [[PMID](#)]
 5. Paladini D, Volpe P. *Ultrasound of Congenital Fetal Anomalies: Differential Diagnosis and Prognostic Indicators.* Oxfordshire United Kingdom: Taylor & Francis Group, LLC; 2014. 31-110 [[DOI:10.1201/b16779](https://doi.org/10.1201/b16779)]
 6. Ceylaner S, Ceylaner G, Günyeli İ, Ekici E, Tuğ M, Taner D, Ekerbicer H, Mollamahmutoğlu L, Danişman N. Postmortem evaluation of 220 prenatally diagnosed fetuses with neural tube defects: detection of associated anomalies in a Turkish population. *Prenatal Diagnosis: Published in Affiliation with Int Soc Prenat Diagn.* 2006; 26(2):147-53. [[DOI:10.1002/pd.1378](https://doi.org/10.1002/pd.1378)] [[PMID](#)]
 7. Lipa M, Pooh RK, Wielgoś M. Three-dimensional neurosonography-a novel field in fetal medicine. *Ginekologia Polska.* 2017; 88(4): 215-21. [[DOI:10.5603/GP.a2017.0041](https://doi.org/10.5603/GP.a2017.0041)] [[PMID](#)]
 8. De Keersmaecker B, Claus F, De Catte L. Imaging the fetal central nervous system. *Facts Views Vis Obgyn.* 2011;3(3):135-49.
 9. Malinger G, Lev D, Lerman-Sagie T. Normal and abnormal fetal brain development during the third trimester as demonstrated by neurosonography. *Eur J Radiol.* 2006; 57: 226-32 [[DOI:10.1016/j.ejrad.2005.11.022](https://doi.org/10.1016/j.ejrad.2005.11.022)] [[PMID](#)]
 10. Milani HJF, Barreto EQS, Araujo Júnior E, Peixoto AB, Nardoza LMM, Moron AF. Ultrasonographic evaluation of the fetal central nervous system: review of guidelines. *Radiol Bras.* 2019; 52(3): 176-81. [[DOI:10.1590/0100-3984.2018.0056](https://doi.org/10.1590/0100-3984.2018.0056)] [[PMID](#)] [[PMCID](#)].

How to Cite This Article:

Golshahi F, Shirazi M, Torabi S, Rahimi Sharbaf F, Nazari F. Normal Assessment of Three Routine Axial Planes in Basic Fetal Neurosonogram Cannot Exclude Encephalocele; Introducing Two Cases. *J Obstet Gynecol Cancer Res.* 2021; 6 (3) :147-151

Download citation:

[BibTeX](#) | [RIS](#) | [EndNote](#) | [Medlars](#) | [ProCite](#) | [Reference Manager](#) | [RefWorks](#)