

Management of Cesarean Myomectomy in a Patient with Multiple Fibroids and an Obstructing Lower Uterine Segment Fibroid

Madhubala Manickavasagam

Department of Obstetrics and Gynecology, Lakshmi Madhavan Hospital, Tamilnadu, India

Article Info

doi:10.30699/jogcr.5.2.57

Received: 2020/08/31;
Accepted: 2020/09/20;
Published Online: 30 Oct 2020;

Use your device to scan and read the article online



ABSTRACT

Background & Objective: Management of caesarean myomectomy (CM) in lower uterine segment obstruction is a hard process. Here I present a pregnant woman with multiple fibroid pregnancy and an obstructing intramural fibroid in the lower segment. The CM procedure was modified here with initially excision of obstructing myoma and delivery of baby.

Case Report: A primigravida woman visited emergency room with abdominal pain at 22 week gestation, receiving antenatal care elsewhere. The emergency abdomen USG showed multiple fibroids in pregnancy with a huge obstructing fibroid in lower segment and a breech presentation with no anomalies. Comparing earlier USG reports exposed that the multiple fibroids were growing across the gestation weeks along the developing fetus. The mother was followed for watchful expectancy till 37 weeks gestation and delivery was planned as elective LSCS. Cesarean myomectomy was carried out through initial excision of lower uterine segment myoma to remove the obstruction, and then deliver the baby through the same incision.

Conclusion: Here the cesarean myomectomy procedure was altered from a regular one, featuring preliminary myomectomy of uterine fibroid in the lower segment, and then delivering the baby and myomectomies again. The outcome was delivering a live baby with hemostasis in a case, with multiple and large fibroids.

Keywords: Altered Caesarean Myomectomy, Breech presentation, Multiple myomas, Obstructing large myoma, Uterine Fibroid growth, Uterine lower segment obstruction

Corresponding Information:

Madhubala Manickavasagam, Department of Obstetrics and Gynecology, Lakshmi Madhavan Hospital, Tamilnadu, India
Email: drmbm25@gmail.com; Tel: 914 622510600



Copyright © 2020, This is an original open-access article distributed under the terms of the Creative Commons Attribution-noncommercial 4.0 International License which permits copy and redistribution of the material just in noncommercial usages with proper citation.

Introduction

Leiomyomas (Uterine Myoma) are tumors found in the uterine smooth muscles, and they are benign in nature. It occurs irrespective of parity status; it is present in non-gravid and gravid uteri. The incidence varies from 217 to 3745 women in 100000 women, and the prevalence varies from 4.5 to 68.6 percent (1). The prevalence of uterine fibroid in pregnant women was 0.5-15 percent (2). Incidence of uterine myoma occupying lower segment and its presence & involvement in the breech presentation of pregnancy were indeterminate.

Here we report a case in which a woman with a history of multiple uterine myomata showing growth with fetal development. The woman underwent C-section with initial myomectomy and through the same incision the baby was delivered in 37 weeks of pregnancy; bilateral internal iliac artery ligation was done to successfully achieve hemostasis along with uterine contraction (3).

Case Report

A 29-year-old primigravida woman with alleged upper abdomen pain visited our emergency room. She was 20 - 22 weeks pregnant, and had received antenatal care elsewhere. At first appointment TVU showing a single viable uterus with a 5-weeks gestation age fetus having fetal heart rate, and it was a multiple fibroid pregnancy. The mother's abdomen size on the 5th gestation week was 6.3 inches, a size relevant to 18-20 weeks of pregnancy this abnormal uterus size was due to fibroid's rapid growth (4).

The follow-up USG at gestation weeks 9 & 12 showed fibroids noticed and multiple larger fibroids with normal nuchal translucency, respectively. Termination of pregnancy was advised by her then obstetrician since the early first trimester. The mother did not accept the termination and continued her pregnancy. She was not diagnosed with uterine fibroid prior to marriage; neither had symptoms nor received treatment for UF (5).

In Emergency Room, USG for weeks 22 revealed Lower anterior wall intramural fibroid (118 × 100 mm) with no detectable anomalies ([Figure 1](#)); fetus showed a breech presentation in all ultrasounds studies; cardiologist echo status was normal, her blood sugar 100 mg/dl; hemoglobin level was 8 g%. She received Inj. Iron Isomaltoside 1000 for anemia.

The UFs were seen growing across the gestation weeks. The Leiomyomata volume outstretched from the initially noted sizes observed in the early weeks of the first trimester which have high-risk pPROM (6). Mother used to have a pain abdomen on and off from her 5th month of pregnancy i.e. 2nd trimester (7).

The delivery was planned as elective lower section cesarean section before the onset of labor as the size of the fibroids was more than 50 mm (8); with myomectomy and bilateral internal iliac artery ligation under spinal anesthesia. She was observed carefully for preterm labor and received tablet Nifedipine 10 mg bid throughout pregnancy and Inj. Dexamethasone 12 mg × 2 doses, intramuscular for fetal lung maturity.

On 37th week, admitted for primary Lower segment Caesarean section (LSCS) delivery; Pfannenstiel incision was done to open the abdomen in layers, the lower segment could not be reached as there was a 150 × 200 mm fibroid sitting on it. An incision was made, degenerated huge myoma dissected, was removed, then through the same incision, uterus was opened and an alive female baby weighing 3000 gram was delivered and APGAR score was 8/10. The baby was in a footling breech presentation.

Posterior to the big fibroid one more fibroid 50 × 40 mm was seen in the lower segment which was also removed; uterus was then sutured in two layers. Another right lateral fundal fibroid, close to the right adnexa of size 150 × 150 mm, was observed in the uterus and was removed and uterus was sutured ([Figure 2. a](#) and [2. B](#)). Bilateral internal iliac artery ligation was done. Bleeding was controlled. A Diathermy vessel sealer was used to cauterize/coagulate blood vessels to prevent excessive bleeding.

Expecting post-operative paralytic ileus, her abdominal girth was checked and it remained as 82 cm on postoperative day-1 & day-2.

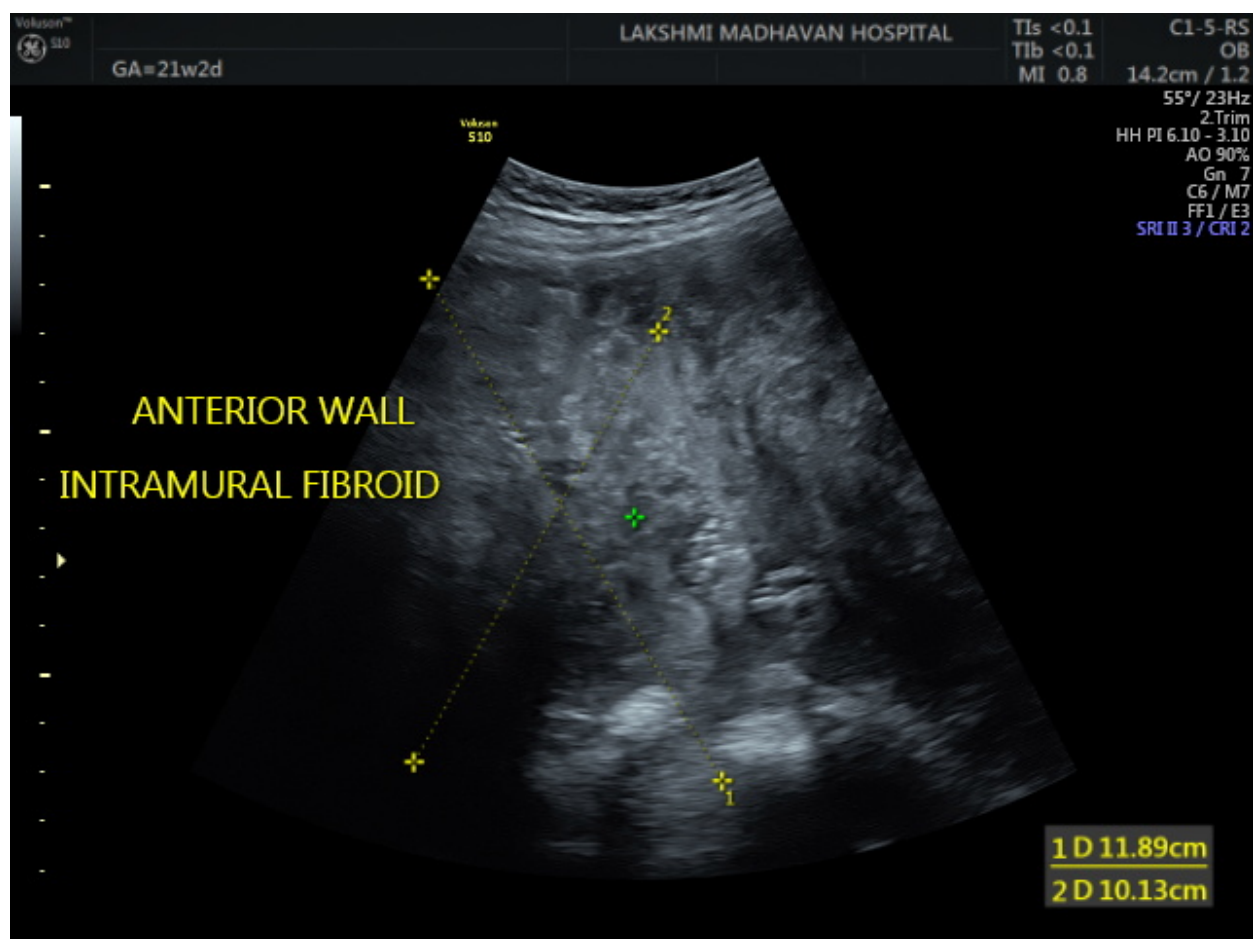


Figure 1. Huge fibroids including intramural fibroid occupying the whole of lower uterine segment in Gestation Week 21

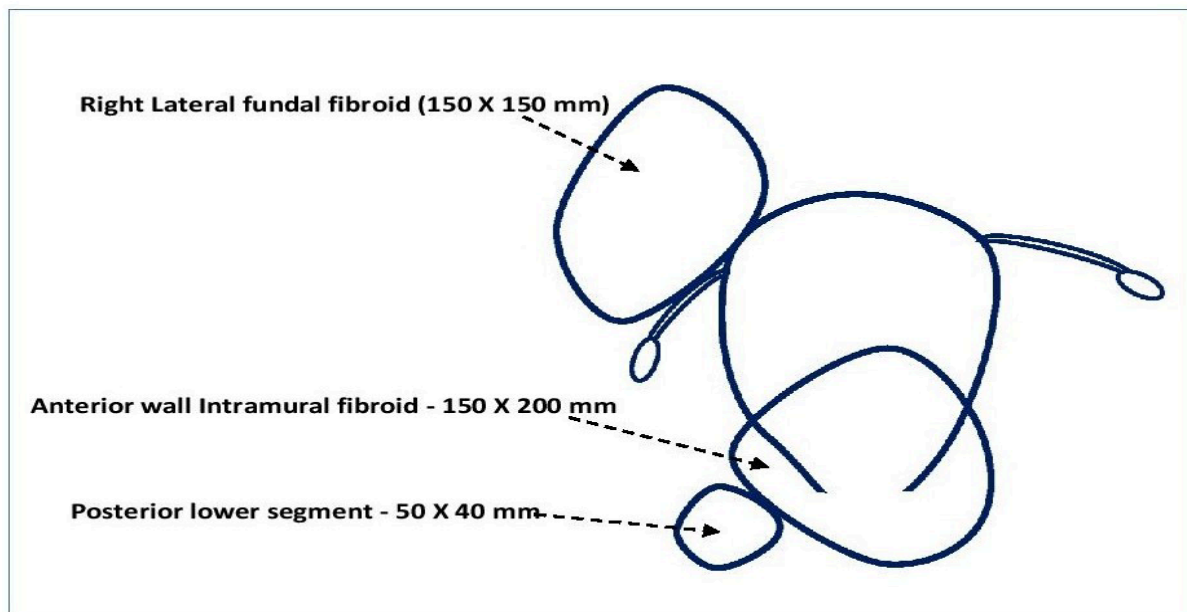


Figure 2. a: Multiple myoma with their size & position in the uterine cavity

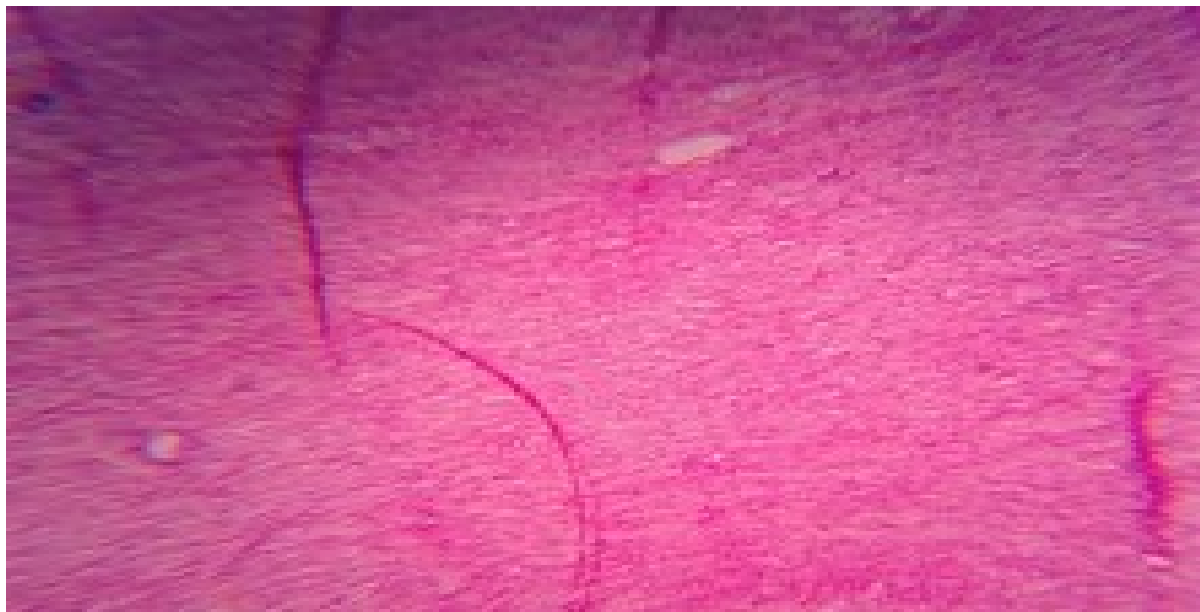

Figure 2. b: Photomicrograph of Leiomyomata with ischemic necrosis

Discussion

Myomectomy was performed initially before the cesarean section as nothing was visible at the incision site other than the huge fibroid and to swiftly proceed for delivering the baby. Usually, myomectomy is performed following the cesarean section, as there is a colossal fibroid occupying the whole of the lower uterine segment, here the regular procedure was performed in reverse.

There was a breech presentation of the baby due to the obstructing huge myoma (9). If the gynecologist and team had a panic in doing a myomectomy, it could be a paramedian (vertical) incision with a classical

cesarean section, which would have involved more problems in the future along with intrauterine bleeding (if fibroids were not removed) and fear of rupture in her next pregnancy.

The presence of intramural fibroids was causing the restriction of the fetal movement. The multiple myomas still kept the fetal immobilized even as early as the first trimester. Breech presentation of fetal position continued to exist even from the first trimester and throughout the pregnancy. The exponential weight gain of the baby in the last weeks of pregnancy pushes the expanding uterine myoma to the lower section

almost occupying the pelvic cavity. A competitive occupancy for the pubic cavity by myoma and fetus, let the fetus to be in the footling presentation. This complication sways on performing both the myomectomy enucleation and also the cesarean; with an additional risk of achieving hemostasis particularly with multiple and large fibroids (7, 10).

Conclusion

Uterine myomas in pregnancy is likely to have positive outcomes. The cumbersomeness of multiple myomas in the uterus gave rise to uterine lower segment obstruction. The access to do a regular cesarean myomectomy was difficult, as the entire lower segment was occupied by a huge anterior wall intramural fibroid. Hence, routine cesarean myomectomy was modified as myomectomy followed by delivery of the baby.

Acknowledgments

The authors thank all those who helped them writing this article.

Conflict of Interest

Authors declared no conflict of interests.

References

1. Stewart EA, Cookson CL, Gandolfo RA, Schulze-Rath R. Epidemiology of uterine fibroids: a systematic review. *BJOG* 2017; 124 (10):1501-12. [DOI:10.1111/1471-0528.14640] [PMID]
2. Cooper NP, Okolo S. Fibroids in pregnancy-common but poorly understood. *Obstet Gynecol Surv.* 2005; 60 (2):132-38.
3. Sapmaz E, Celik H, Altungül A. Bilateral ascending uterine artery ligation vs. tourniquet use for hemostasis in cesarean myomectomy. A comparison. *J Reprod Med.* 2003; 48: 950- 54.
4. Ozturk E, Ugur MG, Kalayci H, Balat O. Uterine myoma in pregnancy: report of 19 patients. *Clin Exp Obstet Gynecol* 2009; 36: 182-83.
5. Mara M, Horak P, Kubinova K, Dundr P, Belsan T, Kuzel D. Hysteroscopy after uterine fibroid embolization: evaluation of intrauterine findings in 127 patients. *J Obstet Gynaecol Res.* 2012; 38(5):823-31. [DOI:10.1111/j.1447-0756.2011.01782.x] [PMID]
6. Ciavattini A, Clemente N, Delli Carpini G, Di Giuseppe J, Giannubilo SR, Tranquilli AL. Number and size of uterine fibroids and obstetric outcomes. *J Matern Fetal Neonatal Med.* 2015; 28 (4):484-88. [DOI:10.3109/14767058.2014.921675] [PMID]
7. Ouyang DW, Economy KE, Norwitz ER. Obstetric complications of fibroids. *Obstet Gynecol Clin North Am.* 2006; 33(1):153-69. [DOI:10.1016/j.ogc.2005.12.010] [PMID]
8. Vergani P, Locatelli A, Ghidini A, Andreani M, Sala F, Pezzullo JC. Large uterine leiomyomata and risk of cesarean delivery. *Obstet Gynecol.* 2007; 109 (2 Pt 1):410-14. [DOI:10.1097/01.AOG.0000250470.78700.f0] [PMID]
9. Qidwai GI, Caughey AB, Jacoby AF. Obstetric outcomes in women with sonographically identified uterine leiomyomata. *Obstet Gynecol.* 2006; 107 (2 Pt 1):376-82. [DOI:10.1097/01.AOG.0000196806.25897.7c] [PMID]
10. Shavell VI, Thakur M, Sawant A, Kruger ML, Jones TB, Singh M, et al. Adverse obstetric outcomes associated with sonographically identified large uterine fibroids. *Fertil Steril.* 2012; 97 (1):107-10. [DOI:10.1016/j.fertnstert.2011.10.009] [PMID]

How to Cite This Article:

Manickavasagam M. Management of Cesarean Myomectomy in a Patient with Multiple Fibroids and an Obstructing Lower Uterine Segment Fibroid. *J Obstet Gynecol Cancer Res.* 2020; 5 (2) :57-60

Download citation:

[BibTeX](#) | [RIS](#) | [EndNote](#) | [Medlars](#) | [ProCite](#) | [Reference Manager](#) | [RefWorks](#)