

The Efficacy of Methotrexate Administration in the Prevention of Persistent Ectopic Pregnancy After Laparoscopic Salpingostomy in Tubal Pregnancy

Zahra Rezaei ¹, Negin Azimi ^{1*}

1. Department of Obstetrics and Gynecology, Yas Women General Hospital, Tehran University of Medical Sciences, Tehran, Iran



Article Info

doi:10.30699/jogcr.6.1.6

Received: 2020/10/01;

Accepted: 2020/11/16;

Published Online: 1 Jan 2021;

Use your device to scan and read the article online



Corresponding Information:

Negin Azimi,

Department of Obstetrics and Gynecology,
Yas Women General Hospital, Tehran
University of Medical Sciences, Tehran, Iran

Email: nanazimi@gmail.com

ABSTRACT

Background & Objective: Persistent ectopic pregnancy (PEP) occurs due to incomplete removal of trophoblastic tissue during tubal pregnancy surgery treatment. If PEP is not diagnosed and treated in time, it can have high mortality and morbidity. This study aimed to evaluate the efficacy of methotrexate (MTX) administration in the prevention of PEP after linear laparoscopic salpingostomy in tubal pregnancy.

Materials & Methods: This randomized clinical trial study was conducted on 140 subjects with a diagnosis of unruptured tubal pregnancy, who were randomly divided into intervention and control groups. While the intervention group underwent a prophylactic injection of 50 mg MTX, the control group did not receive any dose of MTX. PEP was considered if there was an increase in serum BHCG levels or a decrease of less than 20% in serum BHCG levels.

Results: There was no significant difference between the intervention and control groups in terms of baseline variables such as age, severity, parity, and gestational age. While in the intervention group only one patient (1.4%) had PEP, in the control group 11 (15.7%) patients had PEP ($P=0.003$).

Conclusion: MTX administration seems to be an effective method in preventing PEP after linear laparoscopic salpingostomy in tubular pregnancy.

Keywords: Methotrexate, Persistent ectopic pregnancy, Tubular pregnancy



Copyright © 2021, This is an original open-access article distributed under the terms of the Creative Commons Attribution-noncommercial 4.0 International License which permits copy and redistribution of the material just in noncommercial usages with proper citation.

Introduction

Ectopic pregnancy (EP) accounts for about 1 in 100 pregnancies. The most common site of EP is the fallopian tubes, and its clinical signs include amenorrhea or irregular menstruation, unexplained spotting, bleeding in the first trimester, and pain in the lower abdomen, which often occur at 6-8 weeks of gestation (1-4).

A persistent ectopic pregnancy (PEP) occurs due to incomplete removal of trophoblastic tissue during the treatment of tubal pregnancy surgery and its incidence has been reported 3-20% in various studies; this number varies according to the surgical technique (laparotomy or laparoscopy) and the skill of the surgeon (5).

PEP has an increasing trend today due to the increase in laparoscopic surgeries for the treatment of tubal EPs. In conditions including higher levels of early B-HCG, lower gestational age (less than 40 days), and smaller size of pregnancy products (less than 2 cm), there is a

higher risk of remaining pregnancy products after salpingostomy (6-8).

If PEP is not treated in time, it may cause tubal rupture and intra-abdominal bleeding, resulting in high mortality and morbidity; hence, both prevention and early detection of this disorder are important (9-10).

In this regard, a single dose of an anti-trophoblastic drug such as methotrexate (MTX) may be effective during the first 24 hours after salpingostomy (11); but since this drug has many systemic side effects, it should be avoided as much as possible (12-14). The concomitant use of MTX with linear salpingostomy can prevent PEP (9-10).

Studies have shown that use of MTX during laparoscopy or along with transvaginal ultrasound can help reduce PEP cases and their complications (18-15). Therefore, in this study we investigated the effectiveness of using MTX to prevent PEP.

Materials and Methods

This participant of this randomized clinical trial included all females with a diagnosis of unruptured tubular EP referred to Yas Hospital Tehran, Iran in 2014-2016.

The inclusion criteria were women who underwent linear salpingostomy for treatment of unruptured tubular EP, and those who consented to take part in the study.

Exclusion criteria included women with unstable hemodynamic conditions, not willing to maintain fertility, previous EP in the same tube, adhesions, and tubular pregnancy size greater than 5 cm.

This study was carried out in compliance with the Helsinki Declaration and it was approved by the Research Ethics Committee of Tehran University of Medical Sciences (IR.TUMS.MEDICINE.REC.1394.1860). All the patients signed an informed consent letter.

After selecting the participants using a random number table, the subjects were randomly assigned to one of the two intervention or control groups. The intervention group underwent a prophylactic injection of 50 mg of MTX and the control group did not receive MTX. BHCG levels were measured frequently (24 h before the surgery and on the 1-2th, 3-4th, 5-6th, and 7-8th postoperative days) in both groups and PEP was considered if there was an increase in serum BHCG levels or a decrease of less than 20% in serum BHCG levels.

After collecting the required information, the data were analyzed using IBM SPSS Statistics for Windows, version 20 (IBM Corp., Armonk, N.Y., USA). Independent t-test, Chi-square, and Fisher's tests were used and a significance level was considered less than 0.05.

Results

The participants (n=140) were assigned to two equal groups of intervention and control (n=70 in each group). There was no significant difference between the two groups in terms of baseline variables such as age, gravidity, parity, and gestational age.

The mean age of the intervention group was 27.71 ± 6.64 years and the mean age of the control group was 27.7 ± 9.42 years; there was no significant difference between the groups regarding age ($P=0.992$).

The mean number of gravidity in the intervention and control groups was 2.17 ± 1.57 and 2.04 ± 1.61 , respectively, which was not significant ($P=0.634$).

The average parity number in the intervention and control groups was 1.19 ± 1.27 and 1.26 ± 1.36 , respectively, which was not significant ($P=0.750$).

The mean of gestational age in the intervention and control groups was 7.44 ± 1.3 and 7.36 ± 1.16 weeks, respectively, which was not significant ($P=0.683$).

While in the intervention group only one patient (1.4%) had PEP, in the control group 11 patients (15.7%) had PEP, indicating a significant difference ($P=0.003$) (Figure 1).

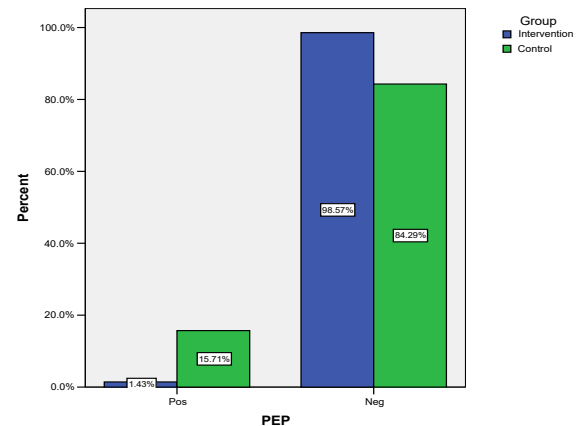


Figure 1. The frequency of persistent ectopic pregnancy (PEP) in study groups

Discussion

Based on the results obtained in this study, 1.4% of the subjects in the intervention group with use of methotrexate and 15.7% in the control group had a persistent ectopic pregnancy, which showed a statistically significant (p -value = 0.003) difference between the two groups.

A study by Robinson *et al.* (2004) in the United States found that PEP could cause delayed bleeding after laparoscopic salpingostomy (19), which confirms our results.

Domsick *et al.* (1991) conducted a case study on PEP after salpingostomy in the United States and reported that MTX can be beneficial in this regard. They also showed that the reduction of BHCG can help in the early diagnosis of PEP (the BHCG level prior to laparoscopy was 1542 mIU/mL on 8th postoperative day, which increased to 3163 mIU/mL, while using MTX led to a 48% decrease in the BHCG level after 72 h). (20). In this study, we also identified PEP based on an increase in serum BHCG levels or a decrease of less than 20% in serum BHCG levels.

In a study by Akira *et al.* (2008) in Japan, the use of MTX was reported to prevent PEP, while 17.5% of patients in the non-MTX group experienced PEP (21), which is consistent with the results obtained in our study.

In a study by Kaya *et al.* (2002) in Turkey, no PEP case was seen after using MTX; however, 14.5% of

non-MTX cases had PEP (22), which confirms the results of our study.

It is suggested that further studies be performed with a larger sample size and in a multi-center base. It is also recommended that patients participating in such studies be followed up for future pregnancy outcomes and the possibility of infertility.

Conclusion

It seems that MTX administration is an effective method in preventing PEP after linear laparoscopic salpingostomy in tubular pregnancy.

Acknowledgments

The authors thank all those who helped them writing this article.

Conflict of Interest

Authors declared no conflict of interests.

References

- Alkatout I, Honemeyer U, Strauss A, Tinelli A, Malvasi A, Jonat W, Mettler L, Schollmeyer T. Clinical diagnosis and treatment of ectopic pregnancy. *Obstet Gynecol Surv.* 2013;68(8):571-81. [DOI:10.1097/OGX.0b013e31829cdbeb] [PMID]
- Zou S, Li X, Feng Y, Sun S, Li J, Egecioglu E, Billig H, Shao R. Comparison of the diagnostic values of circulating steroid hormones, VEGF-A, PIGF, and ADAM12 in women with ectopic pregnancy. *J Transl Med.* 2013;11(1):44. [DOI:10.1186/1479-5876-11-44] [PMID] [PMCID]
- Feng C, Chen ZY, Zhang J, Xu H, Zhang XM, Huang XF. Clinical utility of serum reproductive hormones for the early diagnosis of ectopic pregnancy in the first trimester. *J Obstet Gynaecol Res.* 2013;39(2):528-35. [DOI:10.1111/j.1447-0756.2012.02001.x] [PMID]
- Wu G, Yang J, Xu W, Yin T, Zou Y, Wang Y. Serum beta human chorionic gonadotropin levels on day 12 after in vitro fertilization in predicting final type of clinical pregnancy. *J Reported Med.* 2014;59(3-4):161.
- Seifer DB, Diamond MP, DeCherney AH. Persistent ectopic pregnancy. *Obstet Gynecol Clin North Am.* 1991;18(1):153-9.
- Vermesh M, Silva PD, Rosen GF, Stein AL, Fossum GT, Sauer MV. Management of unruptured ectopic gestation by linear salpingostomy: a prospective, randomized clinical trial of laparoscopy versus laparotomy. *Obstet Gynecol.* 1989;73(3 Pt 1):400-4.
- Murphy AA, Nager CW, Wujek JJ, Kettel LM, Torp VA, Chin HG. Operative laparoscopy versus laparotomy for the management of ectopic pregnancy: a prospective trial. *Fertil Steril.* 1992;57(6):1180-5. [DOI:10.1016/S0015-0282(16)55070-5]
- Barnhart KT. Ectopic pregnancy. *New England Journal of Medicine.* 2009;361(4):379-87. [DOI:10.1056/NEJMc0810384] [PMID]
- Seifer DB, Gutmann JN, Grant WD, Kamps CA, DeCHERNEY AH. Comparison of persistent ectopic pregnancy after laparoscopic salpingostomy versus salpingostomy at laparotomy for ectopic pregnancy. *Obstet Gynecol.* 1993;81(3):378-82.
- Tanaka T, Hayashi H, Kutsuzawa T, Fujimoto S, Ichinoe K. Treatment of interstitial ectopic pregnancy with methotrexate: report of a successful case. *Fertil Steril.* 1982;37(6):851-2. [DOI:10.1016/S0015-0282(16)46349-1]
- Ory SJ, Villanueva AL, Sand PK, Tamura RK. Conservative treatment of ectopic pregnancy with methotrexate. *Am J Obstet Gynecol.* 1986;154(6):1299-306. [DOI:10.1016/0002-9378(86)90716-7]
- Graczykowski JW, Mishell Jr DR. Methotrexate prophylaxis for persistent ectopic pregnancy after conservative treatment by salpingostomy. *Obstet Gynecol.* 1997;89(1):118-22. [DOI:10.1016/S0029-7844(96)00370-5]
- Parker J, Bisks A, Proietto AM. A systematic review of single-dose intramuscular methotrexate for the treatment of ectopic pregnancy. *Aust N Z Obstet Gynecol.* 1998;38(2):145-50. [DOI:10.1111/j.1479-828X.1998.tb02988.x] [PMID]
- Isaacs Jr JD, McGehee RP, Cowan BD. Life-threatening neutropenia following methotrexate treatment of ectopic pregnancy: a report of two cases. *Obstet Gynecol.* 1996;88(4):694-6. [DOI:10.1016/0029-7844(96)00252-9]
- Pansky M, Bukovsky I, Golan A, Langer R, Schneider D, Arieli S, Caspi E. Local methotrexate injection: a nonsurgical treatment of ectopic pregnancy. *Am J Obstet Gynecol.* 1989;161(2):393-6. [DOI:10.1016/0002-9378(89)90529-2]
- Akira S, Ishihara T, Yamanaka A, Takeshita T, Kaseki H, Araki T. Laparoscopy with ultrasonographic guidance of intraamniotic methotrexate injection for ectopic pregnancy. A report of two cases. *J Reprod Med.* 2000;45(10):844-6.

17. Ménard A, Créquat J, Mandelbrot L, Hauuy JP, Madelenat P. Treatment of unruptured tubal pregnancy by local injection of methotrexate under transvaginal sonographic control. *Fertil Steril.* 1990;54(1):47-50. [[DOI:10.1016/S0015-0282\(16\)53635-8](https://doi.org/10.1016/S0015-0282(16)53635-8)]
18. Fernandez H, Benifla JL, Lelaidier C, Baton C, Frydman R. Methotrexate treatment of ectopic pregnancy: 100 cases treated by primary transvaginal injection under sonographic control. *Fertil Steril.* 1993;59(4):773-7. [[DOI:10.1016/S0015-0282\(16\)55858-0](https://doi.org/10.1016/S0015-0282(16)55858-0)]
19. Robinson RD, Ginsburg ES. Persistent tubal pregnancy presenting with delayed hemorrhage from a second implantation of trophoblast on the ovary: a case report. *The J Reprod Med.* 2004;49(8):693-5.
20. Dumesic DA, Hafez GR. Delayed hemorrhage of a persistent ectopic pregnancy following laparoscopic salpingostomy and methotrexate therapy. *Obstet Gynecol.* 1991;78(5 Pt 2):960-2.
21. Akira S, Negishi Y, Abe T, Ichikawa M, Takeshita T. Prophylactic intratubal injection of methotrexate after linear salpingostomy for prevention of persistent ectopic pregnancy. *J Obstet Gynaecol Res.* 2008;34(5):885-9. [[DOI:10.1111/j.1447-0756.2008.00746.x](https://doi.org/10.1111/j.1447-0756.2008.00746.x)] [[PMID](#)]
22. Kaya H, Babar Y, Ozmen S, Ozkaya O, Karci M, Aydin AR, Ozbasar D. Intratubal methotrexate for prevention of persistent ectopic pregnancy after salpingotomy. *The J Am Assoc Gynecol Laparosc.* 2002 Nov 1;9(4):464-7. [[DOI:10.1016/S1074-3804\(05\)60520-8](https://doi.org/10.1016/S1074-3804(05)60520-8)]

How to Cite This Article:

Rezaei Z, Azimi N. The Efficacy of Methotrexate Administration in the Prevention of Persistent Ectopic Pregnancy After Laparoscopic Salpingostomy in Tubal Pregnancy. *J Obstet Gynecol Cancer Res.* 2021; 6 (1) :6-9

Download citation:

[BibTeX](#) | [RIS](#) | [EndNote](#) | [Medlars](#) | [ProCite](#) | [Reference Manager](#) | [RefWorks](#)